



Invasive fungal rhinitis with adnexal involvement caused by *Histoplasma capsulatum* in a cat from a non-enzootic location

Journal of Feline Medicine and Surgery Open Reports
1–6

© The Author(s) 2021

Article reuse guidelines:

sagepub.com/journals-permissions

DOI: 10.1177/2055116921993385

journals.sagepub.com/home/jfmsopenreports

This paper was handled and processed by the American Editorial Office (AAFP) for publication in *JFMS Open Reports*



Catherine R Grinstead¹, Andrew S Hanzlicek² , Heather W Largura² and L Joseph Wheat²

Abstract

Case summary This report describes a cat with a rare form of histoplasmosis: invasive rhinitis with adnexal involvement, mimicking disease more commonly caused by cryptococcosis or aspergillosis. This case is especially noteworthy as it was from an area where histoplasmosis is not enzootic.

Relevance and novel information Invasive fungal rhinitis causes significant morbidity in cats. Diagnostic investigation of more common pathogens includes detection of fungal antigen (*Cryptococcus*) or antifungal antibodies (*Aspergillus*). This case demonstrates that histoplasmosis can present as chronic nasal disease in cats. *Histoplasma* antigen testing provides a non-invasive diagnostic option. Moreover, this case serves as a reminder that histoplasmosis can affect cats anywhere, even in non-enzootic areas.

Keywords: Histoplasmosis; cryptococcosis; fungi; mycoses; mycosis

Accepted: 12 January 2021

Introduction

Histoplasmosis, caused by *Histoplasma capsulatum*, is a soil-borne fungus found worldwide and enzootic to much of the USA east of the Rocky Mountains. Infection occurs via inhalation of aerosolized infective microconidia, produced by sexually reproducing mold in the environment. Once in the body, the microconidia transform into asexually budding yeast. Based on seroprevalence studies, transient or subclinical infections are common in enzootic areas.¹ With chronic infection, dissemination to multiple body systems often occurs.^{2–6} Organs most often involved include the lungs, eyes, lymph nodes, spleen, liver, bone marrow, bones and joints.^{2,3,7} Essentially, any organ can be involved. Compared with cryptococcosis and aspergillosis, histoplasmosis is much less likely to involve the nasal cavity, sinuses and central nervous system.^{6,8} Clinical signs are dependent upon the organ systems involved, and often are non-specific, including anorexia, weight loss, lethargy and fever.^{2–4,6}

In the authors' experience, the diagnosis is often delayed, with the reported median duration of clinical signs being 6 weeks.² This might be, in part, due to suspicion of other more common inflammatory diseases such as cancer, or viral or bacterial infections. Diagnosis is commonly made by a combination of appropriate clinical signs and detecting *Histoplasma* antigen in the blood or urine.^{5,6} Finding *H capsulatum* yeasts in body fluids or tissue samples confirms the diagnosis, as can a positive fungal culture or detecting *H capsulatum* DNA by PCR. Treatment is dependent upon the severity of disease and includes azole antifungal therapy. Prognosis is variable with approximately two-thirds of treated cats surviving 6 months after diagnosis.²

¹Village Veterinary Hospital, Bellingham, WA, USA

²MiraVista Diagnostics, Indianapolis, IN, USA

Corresponding author:

Andrew S Hanzlicek DVM, MS, DACVIM (SAIM), MiraVista Diagnostics, 4705 Decatur Boulevard, Indianapolis, IN 46241, USA
Email: ahanzlicek@miravistalabs.com



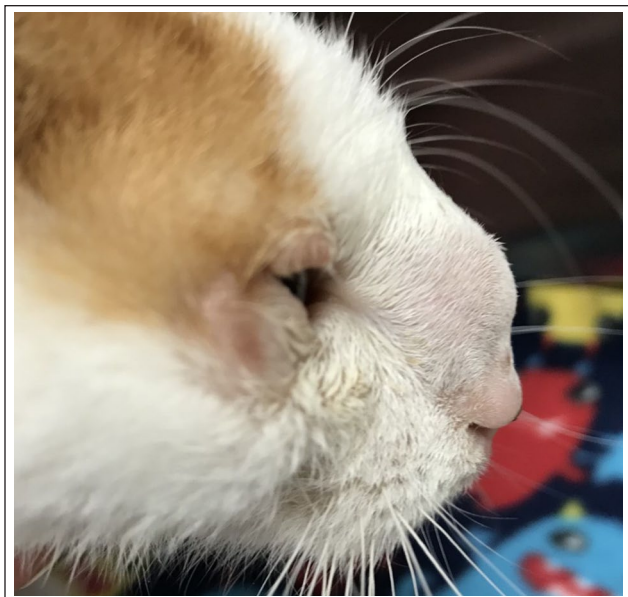

Figure 1 Facial deformity caused by fungal rhinitis in a cat with histoplasmosis

Case description

A 2-year-old neutered male domestic shorthair cat was presented for nasal discharge, sneezing, coughing, and redness and swelling of the conjunctiva. Residing in Washington, the cat was originally rescued from central California as a kitten and had previously tested negative for circulating feline leukemia virus (FeLV) antigen and feline immunodeficiency virus antibodies (SNAP FeLV/FIV; IDEXX). The cat had received initial vaccinations against feline herpesvirus, feline calicivirus, *Chlamydia felis*, feline panleukopenia virus, FeLV and rabies. Upper respiratory viral infection with secondary bacterial infection was diagnosed and amoxicillin/clavulanic acid (31.2 mg/kg PO q12h for 7 days [Clavamox; Zoetis]) was prescribed. Clinical signs improved but failed to resolve completely.

Two weeks after the initial hospital visit, the cat was again presented for continued sneezing, and ocular and nasal discharge. Physical examination was unremarkable and booster vaccinations were administered. Three months after the initial hospital visit, the cat was re-examined for persistent ocular and nasal discharge. Examination revealed a mild fever (103.1°F [39.5°C]), bilateral chemosis and a (0.5 cm diameter) cutaneous nodule near the lateral canthus of the right eye. In-house fine-needle aspiration (FNA) cytopathology of the cutaneous nodule showed suppurative inflammation. Neither bacterial nor fungal organisms were seen. Cytopathology was not submitted for clinical pathologist review. The sample was not submitted to microbial culture. Based on the clinical findings, a presumptive diagnosis of viral upper respiratory infection was made and

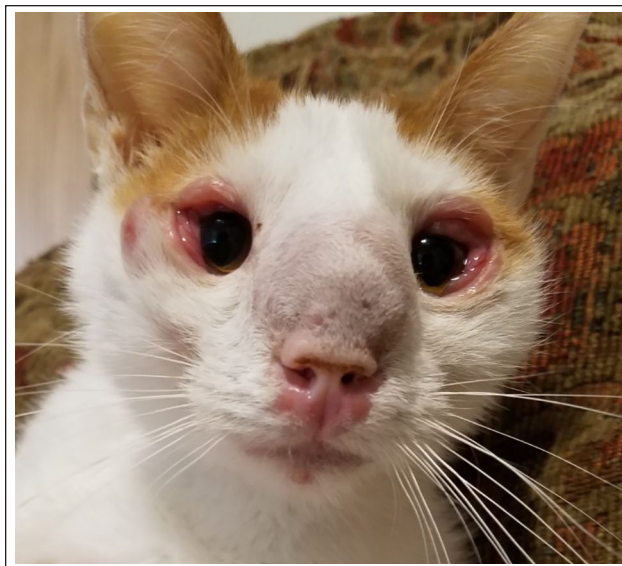

Figure 2 Facial deformity and periocular involvement in a cat with histoplasmosis

topical ophthalmic gentamicin sulfate drops (1 drop in both eyes [OU] q12h for 7 days; Pacific Pharma), orbifloxacin (7.5 mg/kg PO q24h for 7 days [Orbax; Bayer]) and lysine supplementation (250 mg PO q12h indefinite duration [Enisyl-F Lysine Bites; Vetoquinol]) were prescribed.

Two weeks later (3.5 months after the initial hospital visit), the cat was presented for decreased appetite, decreased activity, audible upper respiratory noise, worsening periocular signs, ocular and nasal discharge, and a swollen nose. Physical examination revealed stertor, worsening bilateral chemosis, conjunctivitis, blepharospasm, mucopurulent ocular and nasal discharge, and facial deformity caused by soft tissue swelling over the bridge of the nose (Figures 1 and 2). Based on these findings, fungal rhinitis was considered, with *Cryptococcus* species being most likely, followed by aspergillosis. Owing to the facial deformity and young age of the cat, nasal foreign body and neoplasia, respectively, were considered unlikely. In-house FNA cytopathology of the soft tissue swelling showed granulomatous inflammation, but no bacteria or fungi were seen. The sample was not submitted for review by a clinical pathologist or for microbial culture. A serum latex agglutination test for cryptococcal antigen (Infectious Diseases Lab, University of Georgia) was negative. Owing to the high pretest probability of cryptococcosis, the test was repeated once, on the same sample, and was again negative. While the cryptococcal antigen test was pending, owing to the high suspicion of fungal rhinitis, fluconazole (10 mg/kg PO q12h administered for 5 days [Food and Drug Administration (FDA)-approved generic; manufacturer unknown]) was prescribed. In response to the negative cryptococcal antigen test, the cat was placed under general anesthesia and

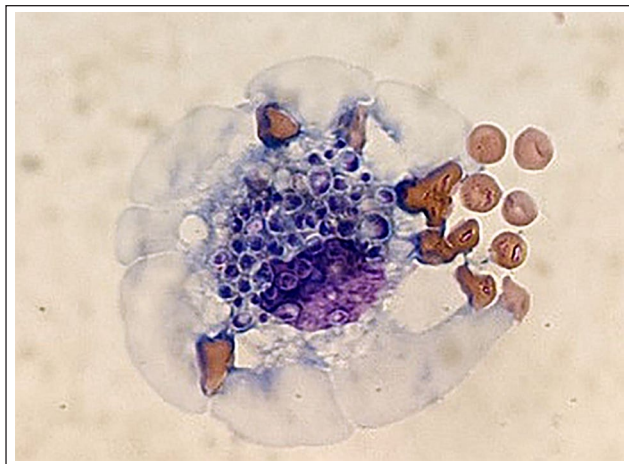


Figure 3 Mostly intracellular *Histoplasma capsulatum* yeasts seen within a macrophage. Yeasts are small (2–5 µm diameter) and round with a thin translucent rim. The nucleus shows dark staining, and is crescent shaped and eccentrically placed. Romanowsky-type stain

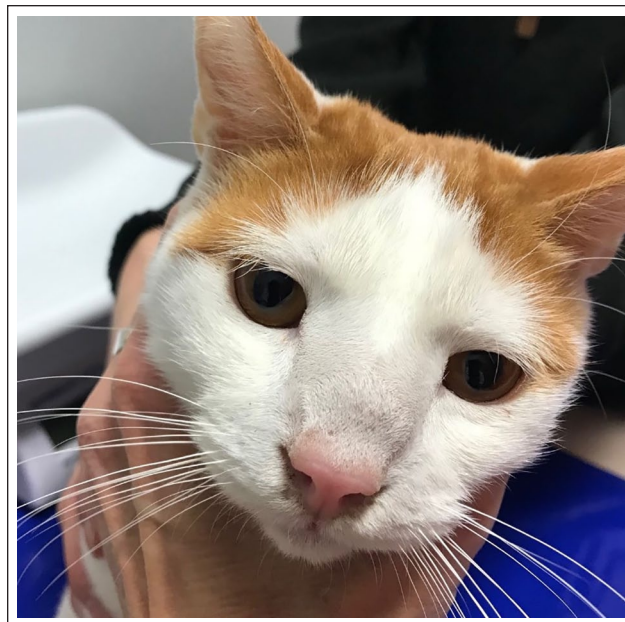

Figure 4 Improved facial deformity and resolved periocular disease in a cat 3 months after treatment for histoplasmosis

the nasal cavity was flushed with 1 ml of 0.9% NaCl, with most of that volume being recovered. Nasal flush infusate was submitted for cytopathology, which revealed pyogranulomatous inflammation with intracellular yeast organisms most consistent with *H capsulatum* (Figure 3). In addition, *H capsulatum* was grown in fungal culture of nasal infusate. Fluconazole was discontinued and itraconazole (5mg/kg PO q12h until disease resolution [Itrafungol; Elanco]) was prescribed. Voriconazole 1% ophthalmic drops (compounded, 1 drop OU q12h for 5 weeks) was prescribed; 0.75 mg dexamethasone (final concentration of 0.05mg/ml) was subsequently added to the drops for anti-inflammatory effects. Robenacoxib (1.4mg/kg q24h for 3 days, then every other day × three doses [Onsior; Elanco]) was also prescribed.

Over the following month (3.5–4.5 months after the initial hospital visit) the ocular and nasal discharge, periocular signs, activity level and appetite improved. The swelling over the nose persisted and terbinafine (compounded, 30mg/kg PO q12h administered for 11 days) was added to the treatment regimen. Within 2 weeks (5 months after the initial hospital visit) the cat developed anorexia, vomiting and diarrhea. Serum biochemistry showed increased alanine transaminase (ALT; 243U/l; reference interval [RI] 12–130U/l) and alkaline phosphatase (ALP) activity (135U/l; RI 14–111 U/l). The remainder of the biochemistry analysis and complete blood count were within the RIs. Owing to suspicion of adverse effects related to terbinafine, terbinafine was discontinued and metronidazole (compounded, 16mg/kg PO q12h for 21 days), capromelin (3mg/kg PO q24h unknown duration [Entyce; Aratana Therapeutics]) and an injection of maropitant (1mg/kg SC once [Cerenia; Zoetis]) were prescribed. Itraconazole was continued as previously prescribed. Soon after, the cat's

appetite quickly improved and vomiting resolved. Two weeks later (5.5 months after the initial hospital visit), ALT was 387U/l (RI 29–111 U/l) and the ALP activity was 103U/l (RI 12–63U/l), which was attributed to itraconazole since the terbinafine had been discontinued. No additional serum chemistries were run.

Over the following 2.5 months (5.5–8 months after the initial hospital visit), nasal and ocular discharge and periocular signs slowly resolved, while the swelling over the nose persisted. For treatment monitoring, approximately 5 months after the initiation of itraconazole, serum and urine were tested for *Histoplasma* antigen with an enzyme immunoassay (MVista *Histoplasma* Antigen Quantitative EIA; MiraVista Diagnostics). Antigen was not detected in serum but was detected in urine (0.4ng/ml; no RI). Itraconazole was continued and the swelling over the nose slowly improved over the following 2.5 months (8–10.5 months after the initial hospital visit). At that time, a repeat *Histoplasma* urine antigen test was negative, and an itraconazole blood level was elevated (>20µg/ml; RI 2–7µg/ml [MVista Itraconazole Bioassay; MiraVista Diagnostics]). Owing to the resolution of clinical signs and a negative urine antigen test, itraconazole was administered for an additional 30 days then discontinued, and 3 months later (14.5 months after the initial hospital visit) a *Histoplasma* urine antigen test remained negative. The negative urine antigen test, absence of clinical signs and continued bony remodeling of the nasal cavity suggested that the cat remained in clinical remission (Figures 4 and 5).



Figure 5 Improved facial deformity and resolved periocular disease in a cat 3 months after treatment for histoplasmosis

Discussion

This report describes a rare manifestation of histoplasmosis in a cat from a non-enzootic area. Findings suggest that histoplasmosis should be considered in cats with chronic nasal disease even in non-enzootic areas. The clinical signs in the present case are classic for sinonasal cryptococcosis or aspergillosis – chronic nasal discharge with facial deformity, facial cutaneous lesions and ocular/adnexal involvement.^{8–12} In contrast, nasal involvement is very uncommon in cats with histoplasmosis.^{3–6} The authors are unaware of a published report describing histoplasmosis primarily manifesting as chronic nasal disease in a cat. The adnexal (conjunctival and nictating membrane) involvement described in this cat has been reported and is estimated to occur in 4% of cats with histoplasmosis.¹³ The reported nodular and crusting facial lesions are more commonly found.^{3,5,14–16}

Like the present case, in the authors' experience, the diagnosis of histoplasmosis in cats is often delayed.² This might be, in part, due to initial clinical suspicion of more common inflammatory diseases. In the present case, initially viral infection seemed more likely owing to the nasal and periocular signs and the relatively higher incidence upper respiratory viral disease compared with fungal rhinitis in cats. As the disease progressed, the facial cutaneous lesion, and especially the facial deformity, suggested a fungal infection was more likely. The cryptococcal latex agglutination antigen test, used in the present case, is highly sensitive (>95%) and specific (>95%) for cryptococcosis.^{8,17} The negative result made cryptococcosis much less likely. A commercially available *Aspergillus* antibody immunodiffusion test is less sensitive (43%) but highly specific (100%) for

sinonasal aspergillosis, but was not performed in this case owing to the relatively lower incidence of sinonasal aspergillosis in cats.¹⁸

In the present case, attempts were made to use FNA cytopathology to identify fungal organisms from the cutaneous lesion and swelling over the bridge of the nose. Both samples showed inflammation, but fungal organisms were not found. While finding intracellular yeast organisms consistent with *Histoplasma* species is considered the 'gold standard' for diagnosing histoplasmosis, these can be difficult to find and can require sampling multiple organs on multiple occasions. Even with extensive sampling, organisms are not always found. Moreover, identifying *Histoplasma* organisms might be even more challenging in a non-enzootic area where veterinarians do not diagnose histoplasmosis on a regular basis. Similarly, a positive fungal culture, along with evidence of pyogranulomatous inflammation on cytopathology, is highly specific but lacks sensitivity for histoplasmosis.¹⁹ In addition, handling *Histoplasma* cultures poses a risk to laboratory personnel and appropriate protective measures are vital. In the present study, nasal sampling led to the discovery of granulomatous inflammation and intracellular yeasts, consistent with *H capsulatum*. This, in combination with a positive fungal culture, provided a definitive diagnosis.

Even after several months of antifungal treatment, the urine *Histoplasma* antigen test was positive, suggesting it could be used as a non-invasive diagnostic option for similar cases. The *Histoplasma* antigen enzyme immunoassay is highly sensitive (94%) and specific (97%) for histoplasmosis in cats and is also useful for treatment monitoring.^{5,6} Based on the fact that antigen concentrations decrease with successful treatment, and antigen testing was not performed at the time of diagnosis, the antigen concentration was likely higher before treatment. While the diagnostic performance of the *Histoplasma* antigen test has not been studied specifically in cats with localized histoplasmosis, the sensitivity is likely lower than for disseminated disease. This presumption is supported by the false-negative results described in the literature, which include cats with ocular, bone and joint, or gastrointestinal involvement.^{7,20,21} Like the present case, antifungal treatment should continue at least 1 month after the first negative urine *Histoplasma* antigen test and resolution of all clinical signs.⁵

The second noteworthy aspect of this case was the geographic locations – California and Washington, which are not areas where histoplasmosis is considered enzootic. In the USA, histoplasmosis in cats is most often seen in the south, south-central and midwestern states, although it is occasionally reported from non-enzootic areas such as California.¹⁶ The sporadic occurrence of histoplasmosis in non-enzootic areas might be partly explained by the environmental suitability for growth of histoplasmosis. A recent study, using statistical modeling of land cover use,

distance to ground water and soil pH showed that an area in California's Central Valley was highly suitable for the growth and sporulation of *H capsulatum*.²² The Central Valley, and the lower San Joaquin valley where this cat was rescued, are the primary agricultural areas of California, so it is conceivable that through irrigation for farming that *H capsulatum* is found more frequently in the environment in these areas. Even within a suitable environment, ecological micro-niches play a role. For example, almost all point-source outbreaks of histoplasmosis in humans are due to some disruption of dust or soil that has been contaminated with bird or bat feces.^{23–26} It is not possible to account for these micro-niches within the larger scale statistical modeling used to determine *H capsulatum* growth suitability. Interestingly, cats confined indoors are also at risk for histoplasmosis and comprise at least one-third of cases, in some reports.^{3,5} This suggests that *H capsulatum* is present, and potentially survives for long periods of time, indoors.

This case report has limitations; most notable is the lack of certain diagnostic testing. As with any veterinary case, all testing was carried out at the final discretion of the pet owner, with testing costs being a consideration. Additional diagnostic testing that might have been useful includes nasal CT, nasal biopsy with histopathology, thoracic radiographs, abdominal ultrasonography, and submandibular lymph node and liver FNA cytopathology. Also lacking, because the cat was rescued, is a complete travel history. Although considered unlikely, it is possible this cat originated from an enzootic region and was transported to California before being rescued.

Conclusions

Even in non-enzootic areas, histoplasmosis should be considered in cats with chronic nasal disease, especially with facial deformity, periocular involvement or facial cutaneous lesions. The urine *Histoplasma* antigen enzyme immunoassay is a non-invasive diagnostic option.

Conflict of interest Wheat JL, Largura H and Hanzlicek AS are employed by MiraVista Diagnostics, which commercially offers the *Histoplasma* antigen enzyme immunoassay used in the reported case.

Funding The authors received no financial support for the research, authorship, and/or publication of this article.

Ethical approval This work involved the use of non-experimental animals only (including owned or unowned animals and data from prospective or retrospective studies). Established internationally recognized high standards ('best practice') of individual veterinary clinical patient care were followed. Ethical approval from a committee was therefore not specifically required for publication in *JFMS Open Reports*.

Informed consent Informed consent (either verbal or written) was obtained from the owner or legal custodian of all animal(s) described in this work (either experimental or

non-experimental animals) for the procedure(s) undertaken (either prospective or retrospective studies). For any animals or humans individually identifiable within this publication, informed consent (either verbal or written) for their use in the publication was obtained from the people involved.

ORCID ID Andrew S Hanzlicek  <https://orcid.org/0000-0001-6523-4033>

References

- Rowley DA, Haberman RT and Emmons CW. **Histoplasmosis: pathologic studies of fifty cats and fifty dogs from Loudoun County, Virginia.** *J Infect Dis* 1954; 95: 98–108.
- Ludwig HC, Hanzlicek AS, KuKanich KS, et al. **Candidate prognostic indicators in cats with histoplasmosis treated with antifungal therapy.** *J Feline Med Surg* 2018; 20: 985–996.
- Reinhart JM, KuKanich KS, Jackson T, et al. **Feline histoplasmosis: fluconazole therapy and identification of potential sources of *Histoplasma* species exposure.** *J Feline Med Surg* 2012; 14: 841–848.
- Aulakh HK, Aulakh KS and Troy GC. **Feline histoplasmosis: a retrospective study of 22 cases (1986–2009).** *J Am Anim Hosp Assoc* 2012; 48: 182–187.
- Hanzlicek AS, Meinkoth JH, Renschler JS, et al. **Antigen concentrations as an indicator of clinical remission and disease relapse in cats with histoplasmosis.** *J Vet Intern Med* 2016; 30: 1065–1073.
- Rothenburg L, Hanzlicek AS and Payton ME. **A monoclonal antibody-based urine *Histoplasma* antigen enzyme immunoassay (IMMY(R)) for the diagnosis of histoplasmosis in cats.** *J Vet Intern Med* 2019; 33: 603–610.
- Fielder SE, Meinkoth JH, Rizzi TE, et al. **Feline histoplasmosis presenting with bone and joint involvement: clinical and diagnostic findings in 25 cats.** *J Feline Med Surg* 2019; 21: 887–892.
- Trivedi SR, Sykes JE, Cannon MS, et al. **Clinical features and epidemiology of cryptococcosis in cats and dogs in California: 93 cases (1988–2010).** *J Am Vet Med Assoc* 2011; 239: 357–369.
- McGill S, Malik R, Saul N, et al. **Cryptococcosis in domestic animals in Western Australia: a retrospective study from 1995–2006.** *Med Mycol* 2009; 47: 625–639.
- Gerds-Grogan S and Dayrell-Hart B. **Feline cryptococcosis: a retrospective evaluation.** *J Am Anim Hosp Assoc* 1997; 33: 118–122.
- Malik R, Wigney DI, Muir DB, et al. **Cryptococcosis in cats: clinical and mycological assessment of 29 cases and evaluation of treatment using orally administered fluconazole.** *J Med Vet Mycol* 1992; 30: 133–144.
- Barrs VR, Halliday C, Martin P, et al. **Sinonasal and sino-orbital aspergillosis in 23 cats: aetiology, clinicopathological features and treatment outcomes.** *Vet J* 2012; 191: 58–64.
- Ewald MM, Rankin AJ, Meekins JM, et al. **Disseminated histoplasmosis with ocular adnexal involvement in seven cats.** *Vet Ophthalmol* 2020; 23: 905–912.
- Clinkenbeard KD, Cowell RL and Tyler RD. **Disseminated histoplasmosis in cats: 12 cases (1981–1986).** *J Am Vet Med Assoc* 1987; 190: 1445–1448.
- Wolf AM and Belden MN. **Feline histoplasmosis: a literature review and retrospective study of 20 new cases.** *J Am Anim Hosp Assoc* 1983; 20: 995–998.

- 16 Johnson LR, Fry MM, Anez KL, et al. **Histoplasmosis infection in two cats from California.** *J Am Anim Hosp Assoc* 2004; 40: 165–169.
- 17 Malik R, McPetrie R, Wigney DI, et al. **A latex cryptococcal antigen agglutination test for diagnosis and monitoring of therapy for cryptococcosis.** *Aust Vet J* 1996; 74: 358–364.
- 18 Barrs VR, Ujvari B, Dhand NK, et al. **Detection of *Aspergillus*-specific antibodies by agar gel double immunodiffusion and IgG ELISA in feline upper respiratory tract aspergillosis.** *Vet J* 2015; 203: 285–289.
- 19 Porter BM, Comfort BK, Menges RW, et al. **Correlation of fluorescent antibody, histopathology, and culture on tissues from 372 animals examined for histoplasmosis and blastomycosis.** *J Bacteriol* 1965; 89: 748–751.
- 20 Smith KM, Strom AR, Gilmour MA, et al. **Utility of antigen testing for the diagnosis of ocular histoplasmosis in four cats: a case series and literature review.** *J Feline Med Surg* 2017; 19: 1110–1118.
- 21 Cook AK, Cunningham LY, Cowell AK, et al. **Clinical evaluation of urine *Histoplasma capsulatum* antigen measurement in cats with suspected disseminated histoplasmosis.** *J Feline Med Surg* 2012; 14: 512–515.
- 22 Maiga AW, Deppen S, Scaffidi BK, et al. **Mapping *Histoplasma capsulatum* exposure, United States.** *Emerg Infect Dis* 2018; 24: 1835–1839.
- 23 Haselow DT, Safi H, Holcomb D, et al. **Histoplasmosis associated with a bamboo bonfire – Arkansas, October 2011.** *MMWR Morb Mortal Wkly Rep* 2014; 63: 165–168.
- 24 Valdez H and Salata RA. **Bat-associated histoplasmosis in returning travelers: case presentation and description of a cluster.** *J Travel Med* 1999; 6: 258–260.
- 25 Davies SF and Colbert RL. **Concurrent human and canine histoplasmosis from cutting decayed wood.** *Ann Intern Med* 1990; 113: 252–253.
- 26 O’Keefe A, Frederick J, Harmon B, et al. **Histoplasmosis outbreak among day camp attendees – Nebraska, June 2012.** *MMWR Morb Mortal Wkly Rep* 2012; 61: 747–748.