



CLINICAL REVIEW

Coccidioidomycosis

Heather Largura DDS, MS, Janelle Renschler DVM, PhD, Joe Wheat MD

See Sykes, J.E. for more detailed information [1].

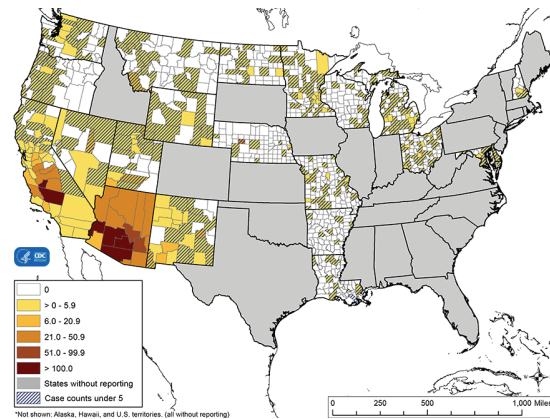
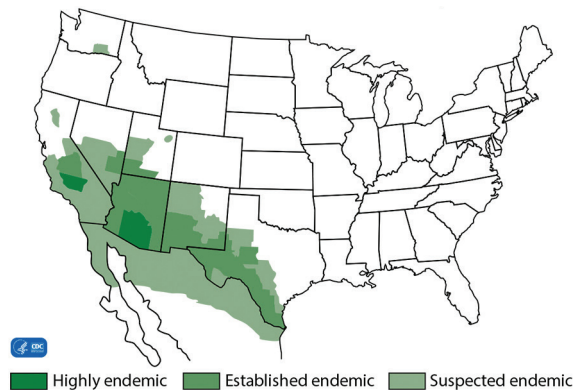
1. Background

- a. Causative agents: *Dimorphic fungi Coccidioides immitis* and *Coccidioides posadasii*.
- b. Route of infection: inhalation of spores, rarely cutaneous inoculation.
- c. At risk: large breed young adult dogs, although dogs of any breed, age, or gender affected [2, 3]. Risk factors for dogs from AZ are being housed outdoors, roaming areas more than 1 acre, and walking in the desert [4]. Coccidioidomycosis occurs less frequently in cats; a recent study demonstrated a high percentage of cats (66%) with coccidioidomycosis had indoor only lifestyle [5, 6]. Exposure to spores can occur through open doors, windows, air conditioners, or fomites that enter the residence.
- d. Endemic distribution: southwestern United States (California, Arizona, Utah, Texas, Nevada, New Mexico), Mexico, Central and South America. Endemic maps demonstrate evidence of coccidioidomycosis in new areas such as the state of Washington and Oregon [7, 8].

2. Clinical Findings in Dogs: most infections are subclinical ~70% [9, 10].

- a. Pulmonary: most common form of coccidioidomycosis, and often accompanied by disseminated findings.
 - i. Signs: tachypnea, cough, dyspnea, exercise intolerance, lethargy, weight loss, anorexia [2, 10]. Cough can be associated with gagging or retching [1].
 - ii. Imaging: unremarkable, most common finding is slight to extensive hilar lymphadenomegaly, sometimes with interstitial pulmonary infiltrates, nodular interstitial, interstitial-alveolar, broncho-interstitial infiltrates and/or sternal lymphadenomegaly [2].

Areas Endemic for Coccidioidomycosis



HEADQUARTERS

4705 Decatur Blvd. | Indianapolis, Indiana 46241, USA

888-841-8387



CLINICAL REVIEW

Coccidioidomycosis *continued*

- b. Disseminated (extrapulmonary): 25%, may be accompanied by pulmonary involvement [2, 10]
 - i. General/systemic:
 - 1. Nonspecific signs: Fever, lethargy, inappetence, and weight loss, diffuse muscle atrophy [3, 11]
 - ii. Cutaneous lesions:
 - Signs: ulcerations with drainage, granulomas, subcutaneous abscesses, may overlie osteomyelitis [1, 3]
 - iii. Peripheral Lymphadenomegaly
 - iv. Ocular involvement:
 - 1. Signs: uveitis, keratitis, conjunctivitis, chorioretinitis, optic neuritis, retinal detachment, and endophthalmitis [2, 12, 13]
 - v. Bone lesions: most common site of dissemination in dogs [1, 10]
 - 1. Signs: lameness, firm swellings, swollen joints, draining lesions, sinus tracts
 - 2. Imaging: osteolytic lesions with periosteal proliferation, can resemble osteosarcomas [3, 5]
 - vi. CNS involvement:
 - 1. Signs: Seizures are most common [10]. Additional signs are obtundation, blindness, nystagmus, absent menace reflexes, diminished gag response, ataxia, abnormal placing reactions, pacing, circling, cervical pain, tetraparesis, [2, 10, 14, 15].
 - 2. Imaging: Plain radiography is not diagnostic for lesions of brain or spinal cord. [10]. Advanced imaging is primary means of differentiating CNS coccidioidomycosis from other neurological diseases, but definitive diagnosis cannot be made on MRI alone [10]. Half of CNS cases have meningoencephalitis [10], brain lesions, ependymitis.
 - vii. Other: cardiac, gastrointestinal, kidneys, bladder, testes, prostate, liver, spleen, GI tract, urinary tract
- 3. Clinical findings in cats:
 - a. Pulmonary
 - i. Signs: tachypnea 25-40% [1, 6]
 - ii. Imaging: bronchial, interstitial and/or alveolar pattern or consolidation of one or more lung lobes 41% [6], hilar lymphadenopathy 27% [5, 6], solitary lung masses or nodules 18% [6], and pleural effusion 24% [6].
 - b. Disseminated (extrapulmonary): 60% present with disseminated infection, perhaps due to delay in seeking care or recognition of infection [6].
 - i. General/Systemic: Fever present in 31-50% [1, 6], inappetence 52% [6]
 - ii. Cutaneous lesions: present in 50-56%, draining skin lesions, subcutaneous granulomas, abscesses [5, 6]. Coccidioidomycosis should be considered in cats from endemic region that present with chronic dermal lesions not responsive to empirical treatment [5, 6].
 - iii. Bone lesions lameness in 20-50% [1, 6]
 - 1. Imaging: periosteal proliferation, osteolysis, soft tissue swelling; can resemble osteosarcoma [1, 3, 5]
 - iv. Ocular involvement: 13%; conjunctival masses, periorbital swelling, chorioretinitis, retinal detachment, endophthalmitis, anterior uveitis [12, 16].
 - v. CNS involvement: hyperesthesia, posterior paresis, seizures, ataxia [1].
 - vi. Other: abdominal organs such as spleen [17].
- 4. Laboratory abnormalities
 - a. CBC: normocytic, normochromic nonregenerative anemia, mild leukocytosis from neutrophilia, monocytosis; lymphopenia.
 - b. Serum chemistry profile: mild to moderate hyperglobulinemia (50%) [1], hypoalbuminemia, uncommonly mild hypercalcemia; increased serum



CLINICAL REVIEW

Coccidioidomycosis *continued*

alkaline phosphatase (ALP) with bony involvement [1, 2, 18]. Cats may have no abnormalities (20%), neutrophilia with or without monocytosis with normal serum chemistries (33%), or hyperglobulinemia (43%) [6].

- c. Urinalysis: occasional proteinuria.
- d. CSF analysis: increased total nucleated cell counts, increased CSF protein and reduced glucose concentration.

5. Diagnosis

a. Histology and cytology:

- i. Advantage: FNA or biopsy easy to perform if cutaneous lesions or lymphadenopathy present and most rapid method for diagnosis. Dermatologic dissemination is frequent in cats, allowing for ease of obtaining sample [5, 19, 20].
- ii. Disadvantage: risk and higher cost if more invasive procedure required in the absence of skin lesions or enlarged lymph nodes (i.e., respiratory specimens or surgical or ultrasound-guided biopsy).

b. Antigen detection:

- i. Advantage: easy to collect specimens, results available in a few days. Combined serum and urine antigen testing, AGID, and antibody EIA yields highest sensitivity (99%) [21].
- ii. Disadvantage: low sensitivity: 20-34% [1, 21, 22] in dogs due to low fungal burden compared to other endemic mycoses, cross reactivity with histoplasmosis (7.7%) and blastomycosis (6.4%) [21]. Sensitivity for antigen test was higher in cats in an unpublished study at MVD (100%; 7/7 cats with proven coccidioidomycosis based on organism ID).

c. Antibody Detection:

- i. Advantage: most sensitive method for diagnosis [23].

a. MVista® *Coccidioides* Canine IgG Antibody Enzyme immunoassay (EIA): high sensitivity/specificity (89.2% / 97%) [21], results same day

b. Immunodiffusion (AGID): high sensitivity (90-92%) [2, 21], but 3 days to result and additional 3 day for titer.

c. Complement fixation test is positive in most cats with coccidioidomycosis [5]. It is not routinely used in dogs due to anticomplementary antibody presence [1].

ii. Disadvantage: No commercially available feline-specific assay.

a. Titer does not reflect severity of disease [9, 24] due to overlap in titer with clinical and subclinical disease [18]. Negative serology does not rule out coccidioidomycosis [18, 25, 26]. Titers 1:8 may be found in 5-20% of healthy dogs.

d. Culture:

i. Advantage: only way to prove the diagnosis. Rarely performed.

ii. Disadvantages: Rarely performed in vet med. Some risk to laboratory personnel, so appropriate facilities are required. Cultures require 1 to 3 weeks incubation, up to 5 weeks occasionally; only used for basis of diagnosis in 12% of cases [9].

e. Molecular: inadequate information to determine usefulness

i. Advantage: fast turnaround time, although no peer-reviewed publications available to assess sensitivity and specificity (making interpretation of the results difficult).

ii. Disadvantage: low incidence of fungemia so whole blood unlikely a desirable specimen, invasive procedure to obtain respiratory or tissue specimens, expensive.



CLINICAL REVIEW

Coccidioidomycosis *continued*

6. Treatment

a. General

- i. Prognosis depends on severity of infection and extent of dissemination [1].

1. Initial hospitalization for intravenous amphotericin B and respiratory assistance may reduce mortality in severe cases.

- ii. Outcome good to excellent in cases with CNS involvement that show resolution of clinical signs in first few weeks of treatment, but poor if deterioration or signs of static encephalopathy, or severe respiratory insufficiency [10].

- b. Amphotericin B: 1 – 3mg/kg every other day, 3 times weekly. Deoxycholate or lipid formulation of amphotericin B are recommended as initial treatment for 3-7 days for cases with severe disease followed by itraconazole to complete therapy. Risk of nephrotoxicity.

- c. Fluconazole: 10mg/kg q24h or 5mg/kg q12h. Fluconazole is the first drug of choice for coccidioidomycosis, with high bioavailability and low toxicity; however, resistance to fluconazole has developed in humans and cats with histoplasmosis [10, 27].

- d. Itraconazole: 5mg/kg PO q 12 hours for 3 days (loading dose) then q 24 hours for dogs; higher doses may be required for cats.

- i. Uncomplicated cases: at least six to twelve months and resolution of signs, resolution or marked improvement of radiographic lesions and resolution of antigen [10].
- ii. Complicated cases (bone, joints, CNS) or relapse despite appropriate therapy. At least 12 months and resolution of signs, radiographic lesions and antigen. In humans with CNS involvement, anti-fungal therapy is lifelong [28]. Human studies show Itraconazole more effective than fluconazole in treating skeletal infections [29].

- iii. Use only FDA approved generic itraconazole or brand named Sporanox®. Compounded non-FDA approved preparations have poor bioavailability [30]. The effectiveness of the non-FDA approved preparations for treatment of coccidioidomycosis is unknown.

- iv. Verify blood levels of itraconazole of at least 2 µg/mL after reaching steady-state (2 weeks in dogs and 3 weeks in cats) is highly recommended [30].

- e. Terbinafine: no published canine studies to support terbinafine, not recommended in humans. A rabbit model comparing terbinafine and fluconazole showed terbinafine to be ineffective in survival, histology and reduction in numbers of colony forming units [28]; no information on whether adequate tissue concentration achieved [10, 28].

- f. Ancillary therapy: glucocorticoids at anti-inflammatory doses for animals with respiratory distress or severe inflammation; however, for short duration [10]. Nonsteroidal anti-inflammatory drugs, tramadol or gabapentin when NSAIDs insufficient, cough suppressants or short-term bronchodilator therapy, antiepileptics for dogs with seizures. Caution should be used with combination of phenobarbital, prednisone, and fluconazole [10]. Drugs metabolized by cytochrome P450 such as phenobarbital will have increased blood levels when used concomitantly with azoles, and glucocorticosteroids can have suppressive effects to the immune system and contribute to hepatopathy in conjunction with azoles.

- g. Surgical management: amputation for persistent osteomyelitis, pericardectomy in tamponade, and enucleation may be required for endophthalmitis [1].

7. Monitoring response to treatment

- a. Resolution of clinical signs and reduction in serological titers, though decision to terminate treatment should not be based on titer alone since titers may plateau or decrease slightly after recovery [23, 31].

HEADQUARTERS

4705 Decatur Blvd. | Indianapolis, Indiana 46241, USA

888-841-8387



CLINICAL REVIEW

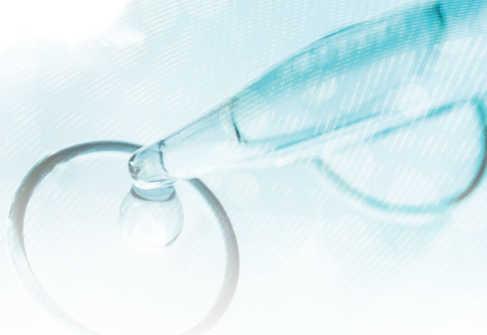Coccidioidomycosis *continued*

- b. *Coccidioides* antibody testing at 3-month intervals during and at 3, 6- and 12-months following discontinuation of treatment, until negative.
 - c. If *Coccidioides* antigen in serum or urine was initially positive, may be useful as a monitoring tool (treat until negative).
 - d. Imaging: resolution or marked improvement in radiographs, CT or MRI scans.
Antifungal susceptibility testing may be performed on cultured isolates. Services available at UT Health San Antonio Fungus Testing Lab.
8. Relapse: up to 25% of dogs relapse [23].
- a. Diagnosis: recurrent signs and increase in antibody titer or antigen concentration.
 - b. Causes: use of non-FDA approved itraconazole, subtherapeutic levels of itraconazole, development of resistance to fluconazole and inadequate duration of treatment [30, 32, 33].
 - c. Treatment:
 - i. Repeat itraconazole adhering to guidelines above.
 - ii. Chronic suppression with itraconazole 5mg/kg administered 3 times weekly may prevent relapse.

HEADQUARTERS

4705 Decatur Blvd. | Indianapolis, Indiana 46241, USA

888-841-8387



CLINICAL REVIEW

REFERENCES

- Sykes, J.E., *Canine and Feline Infectious Diseases*. 2014, St. Louis, MO: Elsevier. 915.
- Johnson, L.R., et al., *Clinical, clinicopathologic, and radiographic findings in dogs with coccidioidomycosis: 24 cases (1995-2000)*. J. Am. Vet. Med. Assoc, 2003. **222**(4): p. 461-466.
- Maddy, K.T., *Disseminated coccidioidomycosis of the dog*. J Am Vet. Med Assoc, 1958. **132**(11): p. 483-489.
- Butkiewicz, C.D., L.E. Shubitz, and S.M. Dial, *Risk factors associated with Coccidioides infection in dogs*. J Am Vet. Med Assoc, 2005. **226**(11): p. 1851-1854.
- Greene, R.T. and G.C. Troy, *Coccidioidomycosis in 48 cats: a retrospective study (1984-1993)*. J Vet. Intern Med, 1995. **9**(2): p. 86-91.
- Arbona, N., et al., *Clinical features of cats diagnosed with coccidioidomycosis in Arizona, 2004-2018*. J Feline Med Surg, 2019: p. 1098612X19829910.
- Marsden-Haug, N., et al., *Coccidioidomycosis Acquired in Washington State*. Clin. Infect. Dis, 2013.
- Lockhart, S.R., O.Z. McCotter, and T.M. Chiller, *Emerging Fungal Infections in the Pacific Northwest: The Unrecognized Burden and Geographic Range of Cryptococcus gattii and Coccidioides immitis*. Microbiol Spectr, 2016. **4**(3).
- Shubitz, L.E., et al., *Incidence of coccidioides infection among dogs residing in a region in which the organism is endemic*. J Am Vet. Med Assoc, 2005. **226**(11): p. 1846-1850.
- Davidson, A.P., et al., *Selected Clinical Features of Coccidioidomycosis in Dogs*. Med Mycol, 2019. **57**(Supplement_1): p. S67-S75.
- Millman, T.M., *Coccidioidomycosis in the dog: its radiographic diagnosis*. J Am Vet Radiol Soc., 1979(20): p. 50-65.
- Angell, J.A., et al., *Ocular coccidioidomycosis in a cat*. J Am Vet. Med Assoc, 1985. **187**(2): p. 167-169.
- Shively, J.N. and C.E. Whiteman, *Ocular lesions in disseminated coccidioidomycosis in 2 dogs*. Pathol Vet, 1970. **7**(1): p. 1-6.
- Burch, M., *Granulomatous meningitis caused by Coccidioides immitis in a dog*. J Am Vet. Med Assoc, 1998. **212**(6): p. 827-829.
- Pryor, W.H., Jr., et al., *Coccidioides immitis encephalitis in two dogs*. J Am Vet Med Assoc, 1972. **161**(10): p. 1108-12.
- Tofflemire, K. and C. Betbeze, *Three cases of feline ocular coccidioidomycosis: presentation, clinical features, diagnosis, and treatment*. Vet. Ophthalmol, 2010. **13**(3): p. 166-172.
- Gaidici, A. and M.A. Saubolle, *Transmission of coccidioidomycosis to a human via a cat bite*. J Clin Microbiol, 2009. **47**(2): p. 505-6.
- Shubitz, L.F. and S.M. Dial, *Coccidioidomycosis: a diagnostic challenge*. Clin. Tech. Small Anim Pract, 2005. **20**(4): p. 220-226.
- Simoes, D.M., et al., *Retrospective analysis of cutaneous lesions in 23 canine and 17 feline cases of coccidioidomycosis seen in Arizona, USA (2009-2015)*. Vet Dermatol, 2016. **27**(5): p. 346-e87.
- Wolf, A.M., *Primary cutaneous coccidioidomycosis in a dog and a cat*. J Am Vet. Med Assoc, 1979. **174**(5): p. 504-506.
- Holbrook, E.D., et al., *Novel canine anti-Coccidioides immunoglobulin G enzyme immunoassay aids in diagnosis of coccidioidomycosis in dogs*. Med Mycol, 2019.
- Kirsch, E.J., et al., *Evaluation of Coccidioides antigen detection in dogs with coccidioidomycosis*. Clin Vaccine Immunol, 2012. **19**(3): p. 343-5.
- Graupmann-Kuzma, A., et al., *Coccidioidomycosis in dogs and cats: a review*. J Am Anim Hosp. Assoc, 2008. **44**(5): p. 226-235.
- LF, B.C.a.S. *A RETROSPECTIVE REVIEW OF CANINE COCCIDI- OIDOMYCOSIS CASES AT A TERTIARY CARE CENTER IN TUC- SON*. in 62nd Annual Coccidioidomycosis Study Group Meeting. 2018. Flagstaff, AZ.
- Crabtree, A.C., D.G. Keith, and H.L. Diamond, *Relationship between radiographic hilar lymphadenopathy and serologic titers for Coccidioides sp. in dogs in an endemic region*. Vet. Radiol. Ultrasound, 2008. **49**(6): p. 501-503.
- Pappagianis, D., *Serologic studies in coccidioidomycosis*. Semin. Respir. Infect, 2001. **16**(4): p. 242-250.
- Renschler, J.S., et al., *Reduced susceptibility to fluconazole in a cat with histoplasmosis*. JFMS Open Rep, 2017. **3**(2): p. 2055116917743364.
- Sorensen, K.N., et al., *Comparative efficacies of terbinafine and fluconazole in treatment of experimental coccidioid meningitis in a rabbit model*. Antimicrob. Agents Chemother, 2000. **44**(11): p. 3087-3091.
- Galgiani, J.N., et al., *Comparison of oral fluconazole and itraconazole for progressive, nonmeningeal coccidioidomycosis - A randomized, double-blind trial*. Annals of Internal Medicine, 2000. **133**(9): p. 676-686.
- Renschler, J., et al., *Comparison of Compounded, Generic, and Innovator-Formulated Itraconazole in Dogs and Cats*. J Am Anim Hosp Assoc, 2018. **54**(4): p. 195-200.
- Greene, R.T., *Coccidioidomycosis, IN: Greene CE, ed. Infectious Diseases of the Dog and Cat*. 1998, Philadelphia: WB Saunders.
- Kriesel, J.D., et al., *Persistent pulmonary infection with an azole-resistant Coccidioides species*. Med Mycol, 2008: p. 1-4.
- Thompson, G.R., 3rd, B.M. Barker, and N.P. Wiederhold, *Large-Scale Evaluation of In Vitro Amphotericin B, Triazole, and Echinocandin Activity against Coccidioides Species from U.S. Institutions*. Antimicrob Agents Chemother, 2017. **61**(4).

HEADQUARTERS

4705 Decatur Blvd. | Indianapolis, Indiana 46241, USA

888-841-8387