



CLINICAL REVIEW

Review of Coccidioidomycosis in Animals

J.S. Renschler, DVM, PhD, Dipl ACVP and L.J. Wheat, MD

1. Introduction

Coccidioidomycosis (“Cocci”), otherwise known as Valley Fever, San Joaquin Valley Fever or desert fever is caused by the dimorphic fungi, *Coccidioides immitis* and *Coccidioides posadasii*. The majority of reported cases are in dogs [1] and cats [2], but any mammalian species is at risk, including horses, pigs, cattle, rodents, marine mammals, etc. [3-11]. Cocci is prevalent in the southwestern United States and Mexico, and is the most commonly recognized cause of systemic mycosis in this region. In a study conducted to evaluate the incidence of Cocci in dogs from Pima (Tucson) and Maricopa (Phoenix) Arizona, 11% were infected by one year of age and 28% by the age of two [1]. Clinical features include acute and chronic pneumonia and disseminated disease with a variety of extra-pulmonary manifestations including meningitis. Diagnosis may be difficult in some cases, and is usually made based upon positive serologic tests for antibodies or visualization of spherules in the tissues. Antigen detection, which is of proven accuracy for rapid diagnosis of veterinary cases of histoplasmosis and blastomycosis, is less sensitive in dogs with Cocci. Combined antigen and antibody testing improves the sensitivity over antibody testing alone. Azole antifungal drugs such as fluconazole or itraconazole are most commonly used for therapy. Newer triazoles, voriconazole and posaconazole, are also effective in treating Cocci but have not been studied in clinical trials in veterinary cases.

2. Epidemiology

Cocci is endemic in the hot, semi-arid southwestern United States (with highly endemic foci in central California and southern Arizona), northern Mexico, and Central America. The endemic range in the United States also includes Nevada, New Mexico, Texas, Utah and possibly Washington (see Fig 1).

The etiological agents are *Coccidioides immitis*, most often seen in California or *Coccidioides posadasii*, seen in Arizona. Cocci grows in the soil as mycelia with laterally

Areas Endemic for Coccidioidomycosis

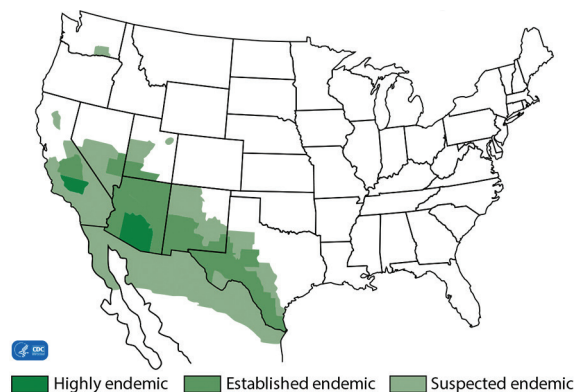


Figure 1. Endemic range of Cocci in the U.S. and Mexico (Centers for Disease Control and Prevention website, cdc.gov, accessed 9/21/16)

growing “barrel” shaped arthroconidia. Cocci lies dormant in the mycelial phase during times of drought, but heavy rain causes germination of the arthroconidia and production of more mycelia. Infection occurs most often during dry weather when conidia are easily dispersed following periods of heavy rain [12, 13]. Wind or disturbances to the soil also promote exposure.

Though most cases occur within the endemic areas, Cocci has been detected in humans or animals that have traveled to endemic areas. Cases also have been reported in subjects with no exposure to the endemic areas, presumably caused by exposure to dust on cars that had been driven through endemic areas [14]. Recent studies have shown that dogs may serve as sentinels for estimating the risk of Cocci [15, 16].

3. Pathogenesis

In nearly all cases, infection occurs by inhalation of the arthroconidia. Fewer than ten arthroconidia can initiate infection [17]. Once inhaled, arthroconidia are distributed through the alveoli, where they are phagocytosed and

HEADQUARTERS

4705 Decatur Blvd. | Indianapolis, Indiana 46241, USA

888-841-8387



CLINICAL REVIEW

develop into spherules, which then enlarge and undergo endosporulation. Once rupture of spherules occurs, endospores are released into surrounding tissue and spread locally or disseminate hematogenously to extra pulmonary sites. These endospores then develop into spherules and continue the cycle, until host control is achieved [12, 18, 19]. The time between inhalation of arthroconidia to formation of spherules is approximately 48-72 hours; however, clinical signs of respiratory illness usually do not manifest for 2 or more weeks [12, 18]. Infection also may occur by accidental inoculation into the skin following sharp injuries with contaminated instruments [20]. Cocci is not communicable [19] except in rare cases in humans in which transmission has occurred by transplantation of an infected organ [21] or accidental inoculation into the skin. Reactivation of latent disease may also occur in immunosuppressed patients [21].

Cell mediated immunity is the key mechanism of defense in Cocci [17, 22-25]. T-lymphocytes predominate in lesions in dogs with Cocci [26]. T-lymphocytes recognizing *Coccidioides* antigens are produced during the first 4-6 weeks of infection and activate macrophages to halt progression. Humans with impaired cellmediated immunity experience severe forms of progressive Cocci. The factors that predispose humans to advanced Cocci are AIDS, solid organ transplantation, immunosuppression, malignant conditions, pregnancy, diabetes, old age, African American race and Filipino ethnicity. Though antibodies are produced in Cocci, they are not believed to play a significant role in recovery from the infection [27].

4. Risk Factors

In dogs, factors that place an animal at higher risk of Cocci are younger age (<6 years old), large breed, and working and sporting breeds. Dogs that are outdoors during the day are five times more likely to become infected [28]. Increased roaming space and walking in the desert increase risk of infection. Though infection is common in dogs from endemic counties, most do not show clinical signs [1]. In cats there appears to be no breed predilection; however, middle aged cats experience Cocci more commonly. Feline leukemia and feline immunodeficiency virus are not thought to increase susceptibility to Cocci [29].

5. Clinical Presentation

Dogs with Cocci present with a variety of clinical signs, most commonly including fever, cough, anorexia, and lethargy. Between 60% and 80% of dogs exhibit pulmonary involvement alone [17, 30], while cats are more likely to exhibit findings of disseminated Cocci [29].

Pulmonary. In dogs a chronic dry or moist cough, often described as retching, low grade fever, anorexia, weight loss, listlessness, and depression are prominent findings. Cough can be caused by lung involvement or constriction of the trachea due to enlarged mediastinal and/or hilar lymph nodes. Radiographic abnormalities are present in about three quarters of cases, of which about half lack respiratory signs [30].

Radiographs usually show hilar or mediastinal lymphadenopathy (50 to 75%) with or without pulmonary infiltrates [29-31]. Hilar or mediastinal lymphadenopathy, although not specific for Cocci, may be the basis for empirical treatment in suspected cases [31]. Lung involvement may be characterized by consolidation, diffuse interstitial or miliary infiltrates, or pulmonary nodules [30, 31]. Only 25% of cats with Cocci present with respiratory signs [29], even though lung involvement was noted at necropsy in nearly all fatal cases [17]. Radiographic findings in cats include hilar lymphadenopathy, pneumonia, pleural effusions and pleural thickenings [29]. These findings indicate that radiography may be useful in the absence of respiratory signs or symptoms in dogs and cats in which Cocci is suspected.

Disseminated. Disseminated disease in dogs commonly presents as lameness due to osteomyelitis [14, 30, 32]. Appendicular bone involvement is most common. Additional signs of disseminated disease include draining tracts in skin, bone tenderness and swelling, and regional lymphadenopathy. Signs of dissemination to the CNS include seizures, ataxia, behavioral changes and coma. Cardiac involvement manifests as heart failure, arrhythmia, syncope, and sudden death. Cocci is known to be a clinical imitator of neoplasia, including bone neoplasia, lung neoplasia, lymphoma, etc. [33].

In cats, draining skin lesions, abscesses, subcutaneous masses, and regional lymphadenopathy are the most prevalent signs, found in over half of cases [29]. Other sites of



CLINICAL REVIEW

dissemination include musculoskeletal lesions, presenting as lameness in most cases [29]. Neurological and ocular abnormalities occur in about 20% of cases, and present as blindness, uveitis, iritis, paresis, seizures, and impairment of coordination.

6. Diagnosis

To diagnose Cocci, one must first suspect it. In one report, the diagnosis had been considered in only 13% of cases prior to referral [30]. The clinical signs resemble those in a variety of other infectious, malignant, and inflammatory or immunologic conditions, further complicating the diagnosis. The optimal approach requires use of multiple diagnostic tests [34].

Microscopy and culture. In one study, seven of 24 (29%) dogs were diagnosed based upon visualization of spherules or isolation of the organism [30]. In cats, the diagnosis was based on cytology, histology or culture in 71% [29]. Draining skin lesions and pleural fluid are more likely to contain spherules than are respiratory samples. Culture may provide the sole laboratory basis for diagnosis [30], but delays of up to 3 weeks and risk to laboratory personnel are limitations.

Antibody detection. Demonstration of antibodies to *Coccidioides* is the basis for diagnosis of most canine cases [29, 30]. The agar gel immunodiffusion (AGID) method detects IgM antibodies against the tube precipitin antigen (AGID-TP) and IgG antibodies to the complement fixation antigen (AGID-CF). AGID was positive in all 20 canine cases that were tested in one study [30], showing IgG antibodies alone or combined with IgM in 19 and IgM antibodies alone in one case. In cats, the diagnosis was based on cytology, histology or culture in 71% and serology in 29% of cases in one report, but of those in which AGID was performed, IgG antibodies were detected in all and IgM antibodies in 83% [29]. Detection of antibodies by AGID may not distinguish active from past infection, however, representing a limitation of antibody detection. While a titer of 1:16 or above is more suggestive of active disease [8, 17], titers were 1:8 or below in 43% of proven cases [30]. Titers may be 1:16 or higher in dogs without clinical findings for active Cocci [1]. High titers are associated with a more severe disease and death

in horses [35]. Furthermore, a negative AGID antibody test does not exclude Cocci, and the optimal approach requires use of multiple diagnostic tests [34]. Repeat testing in 3 to 4 weeks may yield positive results if initial tests were negative [34, 35] or indeterminate (AGID titers between undiluted and 1:8).

An enzyme immunoassay (EIA) for detection of IgG antibodies (MVista® *Coccidioides* canine IgG Antibody EIA) offers an alternative to AGID. The EIA has the advantage of more rapid turnaround time (1 day compared to 3-7 days for AGID). The EIA also is easier to perform and requires less technician time. Results are semiquantitative and do not require side-by-side testing of current and prior specimens, as recommended for AGID.

Antigen Detection. *Coccidioides* antigen detection is useful for diagnosis of Cocci in humans, with positive results in about 70% of cases [36, 37]. The sensitivity in dogs, however, is much lower as antigen was detected in the urine or serum in only 19% of cases [24]. In that study, the diagnosis was based upon serology in 96% and microscopy in 4%.

Antigen detection may be useful for monitoring therapy, based on unpublished experience in humans, dogs and cats with Cocci and published experience in dogs with blastomycosis [38].

Comparison of Test Methods: In one study, 21 dogs with proven Cocci (based on identification of the organism by cytology, histopathology or culture) were evaluated [39]. AGID was positive for CF antigen in 16/21 (76.1%), although titer was $\geq 1:4$ in only 14/21 (66.7%). IgG by EIA was positive in 18/21 Cocci dogs (85.7%; $p=0.125$ compared to AGID $\geq 1:4$). Antigen was detected in urine or serum in only 9/21 (42.9%) Cocci dogs. IgG or antigen was detected in 20/21 (95.3%), and AGID, IgG or antigen were positive in all dogs (100%). Combined IgG and antigen testing, or testing all 3 methods improved sensitivity over AGID $\geq 1:4$ only; $p<0.05$. Specificity in healthy dogs was 90.6% (29/32) for either AGID or antibody EIA, and 100% for antigen test. Specificity for all tests was 100% for clinical control dogs.



CLINICAL REVIEW

The results of this method comparison indicated that the IgG antibody EIA and AGID have similar sensitivity, although the EIA is still advantageous due to the faster turnaround time. Future studies with a larger number of cases may be able to show a statistically significant difference in sensitivity. Also noteworthy is that the antigen test was able to detect occasional seronegative cases; therefore, the highest sensitivity is likely achieved by assessing both antigen and antibody.

Molecular techniques. The role of PCR for diagnosis of Cocci in veterinary patients remains to be determined. One report describes the use of PCR in a llama with Cocci [40].

7. Treatment

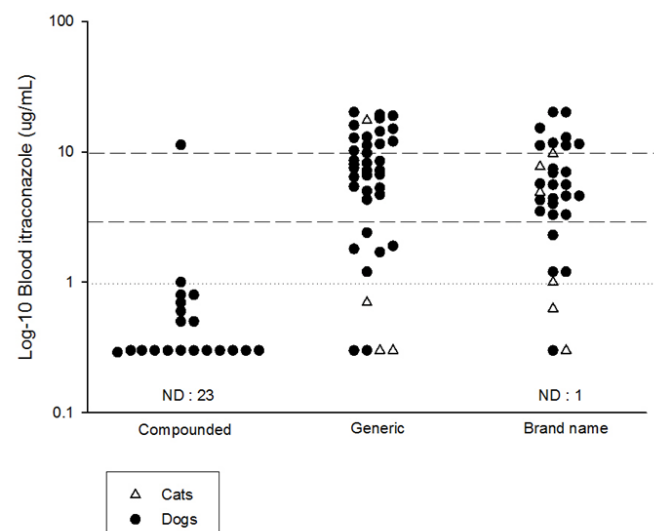
Antifungal therapy typically involves azoles and possibly amphotericin B. Amphotericin B is effective, but must be given intravenously and causes many side effects, including renal impairment. Newer lipid-encapsulated forms are less toxic than the traditional deoxycholate form, although cost is much higher. In humans, amphotericin B is reserved for cases with rapidly progressing disease or for those who are unable to take or have failed azole therapy [13]. Treatment guidelines for use of amphotericin B in animals are available in the Veterinary Drug Handbook [41] and are reviewed elsewhere [17].

Fluconazole. Fluconazole is the treatment of choice in most cases and can be given intravenously or orally. Fluconazole crosses the blood brain barrier and penetrates ocular fluids making it the medication of choice in patients with CNS or eye involvement [34]. The typical dose for dogs is 5-10 mg/kg PO given BID. Due to low molecular weight and high water solubility, high bioavailability is achieved with oral administration; therefore, therapeutic drug monitoring is usually unnecessary. Potential side effects include vomiting, diarrhea and hepatotoxicity, although fluconazole is typically better tolerated (and less likely to cause hepatotoxicity) compared to itraconazole.

Itraconazole. Itraconazole concentrates in the skin and may be preferred in patients with cutaneous [42] or bone lesions [13]. Itraconazole is not as well tolerated as fluconazole and is typically more expensive. Due to the high cost of innovator-formulated itraconazole (Sporanox[®], Janssen Pharmaceuticals), many veterinarians have attempted to use compounded preparations, but these should be avoided because they exhibit poor bioavailability [28, 43]. Generic itraconazole capsules are more reasonably priced and achieve blood levels and effectiveness comparable to brand name Sporanox[®] (43; see Fig 2). Itraconazole capsules require an acid pH for maximum absorption, and should be taken with food.

Blood levels of itraconazole should be measured 14 days (dogs) to 21 days (cats) after beginning therapy, and the preferred range is 2.0 µg/mL to 7.0 µg/mL as measured by bioassay, and at least 1.0 µg/mL by HPLC. As itraconazole has a long half-life, timing of the specimen after dosing is not

Figure 2. Itraconazole blood levels in dogs and cats receiving compounded, generic pelleted or brand name (Sporanox[®]) itraconazole. Dashed lines indicate limits of therapeutic range (3-10 µg/mL) and dotted line indicates lower limit of equivocal range (1-2.0 µg/mL). ND=none detected.





CLINICAL REVIEW

critical but trough levels are preferred. If itraconazole levels using generic or brand-name pelletized itraconazole are below 2 µg/mL by bioassay, or 1 µg/mL by HPLC, the dosage should be increased and blood levels should be rechecked at 14 days (dogs) to 21 days (cats) later. Inability to achieve concentrations above 2 µg/mL would be a reason to change to fluconazole.

Itraconazole may cause a variety of adverse effects, most commonly loss of appetite, anorexia, vomiting, or diarrhea, which may be related to elevated blood concentration [31]. Serum liver enzymes should be monitored during therapy. Activity of serum alanine aminotransferase (ALT) greater than 200 U/L may warrant discontinuation of itraconazole until appetite returns and ALT activity returns to <100 U/L [31]. Itraconazole may be restarted at half of the former dose. Ulcerative dermatitis was also observed in 7.5% of dogs receiving itraconazole at 10 mg/kg/d [23].

Treatment duration. The duration of treatment for Cocci is often unclear, and decisions to terminate antifungal therapy are often made based on resolution of clinical signs and radiographic lesions as well as serologic titers. Long-term monitoring of AGID titers is beneficial, as rising titers suggest a poor therapeutic response. CF titers may stabilize or decrease only slightly over time. The antibody EIA has not yet been studied in serial samples during therapy for Cocci, although IgG values would also likely decrease over time with successful therapy. Increases in antigen concentration after stopping treatment suggests relapse, which occurs in about 15-20% of cases treated with either itraconazole [17, 23, 29, 30] or fluconazole [29].

Other antifungals: The role of the newer triazoles (posaconazole, voriconazole, isavuconazole) is uncertain. Posaconazole and voriconazole are active against *Coccidioides* and have been used successfully in a small number of cases in humans [44]. Posaconazole was used in a chimpanzee after failing fluconazole [45], and voriconazole was used successfully in a Pacific walrus with Cocci [9]. These newer triazoles are more expensive than itraconazole, and require monitoring to assure adequate blood levels.

Isavuconazole is active in vitro against *Coccidioides* [46], but has not been studied in humans or animals and is not yet commercially available. Nikkomycin, a chitin synthase inhibitor, is active in vitro and was effective in naturally infected dogs with Cocci [47] but is not commercially available. The echinocandins, which work by inhibiting glucan synthase, show in vitro activity [48] and efficacy in experimental models [49] and a few humans [50, 51] but their effectiveness and role for treatment of Cocci has not been established.

HEADQUARTERS

4705 Decatur Blvd. | Indianapolis, Indiana 46241, USA

888-841-8387



CLINICAL REVIEW

References

- Shubitz LE, Butkiewicz CD, Dial SM, Lindan CP. Incidence of *Coccidioides* infection among dogs residing in a region in which the organism is endemic. *J Am Vet Med Assoc* 2005 Jun 1; 226(11):1846-50.
- Lloret A, Hartmann K, Pennisi MG, et al. Rare systemic mycoses in cats: blastomycosis, histoplasmosis and *Coccidioidomycosis*: ABCD guidelines on prevention and management. *J Feline Med Surg* 2013 Jul; 15(7):624-7.
- Cafarchia C, Figueredo LA, Otranto D. Fungal diseases of horses. *Vet Microbiol* 2013 Nov 29; 167(1-2):215-34.
- Ziemer EL, Pappagianis D, Madigan JE, Mansmann RA, Hoffman KD. *Coccidioidomycosis* in horses: 15 cases (1975-1984). *J Am Vet Med Assoc* 1992 Sep 15; 201(6):910-6.
- Prchal CJ, Crecelius HG. *Coccidioidomycosis* in swine. *J Am Vet Med Assoc* 1966 May 15; 148(10):1168-9.
- Prchal CJ. *Coccidioidomycosis* of cattle in Arizona. *J Am Vet Med Assoc* 1948 Jun; 112(855):461-5.
- Stewart AJ, Cuming RS. Update on fungal respiratory disease in horses. *Vet Clin North Am Equine Pract* 2015 Apr; 31(1):43-62.
- Higgins JC, Leith GS, Voss ED, Pappagianis D. Seroprevalence of antibodies against *Coccidioides immitis* in healthy horses. *J Am Vet Med Assoc* 2005 Jun 1; 226(11):1888-92.
- Schmitt TL, Procter DG. *Coccidioidomycosis* in a Pacific walrus (*Odobenus rosmarus divergens*). *J Zoo Wildl Med* 2014 Mar; 45(1):173-5.
- Catalan-Dibene J, Johnson SM, Eaton R, et al. Detection of *Coccidioides* antibodies in serum of a small rodent community in Baja California, Mexico. *Fungal Biol* 2014 Mar; 118(3):330-9.
- Huckabone SE, Gulland FM, Johnson SM, et al. *Coccidioidomycosis* and other systemic mycoses of marine mammals stranding along the central California, USA coast: 1998-2012. *J Wildl Dis* 2015 Apr; 51(2):295-308.
- Kirkland TN, Fierer J. *Coccidioidomycosis*: a reemerging infectious disease. *Emerg Infect Dis* 1996 Jul; 2(3):192-9.
- Galgiani JN, Ampel NM, Blair JE, et al. *Coccidioidomycosis*. *Clin Infect Dis* 2005 Nov 1; 41(9):1217-23.
- Maddy KT. Disseminated *Coccidioidomycosis* of the dog. *J Am Vet Med Assoc* 1958 Jun 1; 132(11):483-9.
- Gautam R, Srinath I, Clavijo A, et al. Identifying areas of high risk of human exposure to *Coccidioidomycosis* in Texas using serology data from dogs. *Zoonoses Public Health* 2013 Mar; 60(2):174-81.
- Grayzel SE, Martinez-Lopez B, Sykes JE. Risk factors and spatial distribution of canine *Coccidioidomycosis* in California, 2005-2013. *Transbound Emerg Dis* 2016; doi: 10.1111/tbed.12475. [Epub ahead of print].
- Graupmann-Kuzma A, Valentine BA, Shubitz LF, Dial SM, Watrous B, Tornquist SJ. *Coccidioidomycosis* in dogs and cats: a review. *J Am Anim Hosp Assoc* 2008 Sep; 44(5):226-35.
- Cox RA, Magee DM. *Coccidioidomycosis*: host response and vaccine development. *Clin Microbiol Rev* 2004 Oct; 17(4):804-39.
- Stevens DA. *Coccidioidomycosis*. *N Engl J Med* 1995; 332(16):1077-82.
- Wilson JW, Smith CE, Plunkett OA. Primary cutaneous *Coccidioidomycosis*; the criteria for diagnosis and a report of a case. *Calif Med* 1953 Sep; 79(3):233-9.
- Vikram HR, Blair JE. *Coccidioidomycosis* in transplant recipients: a primer for clinicians in nonendemic areas. *Curr Opin Organ Transplant* 2009 Dec; 14(6):606-12.
- Lehmann PF. Immunology of fungal infections in animals. *Vet Immunol Immunopathol* 1985 Oct; 10(1):33-69.
- Hung CY, Gonzalez A, Wuthrich M, Klein BS, Cole GT. Vaccine immunity to *Coccidioidomycosis* occurs by early activation of three signal pathways of T helper cell response (Th1, Th2, and Th17). *Infect Immun* 2011 Nov; 79(11):4511-22.
- Nesbit L, Johnson SM, Pappagianis D, Ampel NM. Polyfunctional T lymphocytes are in the peripheral blood of donors naturally immune to *Coccidioidomycosis* and are not induced by dendritic cells. *Infect Immun* 2010 Jan; 78(1):309-15.
- Ampel NM. The complex immunology of human *Coccidioidomycosis*. *Ann N Y Acad Sci* 2007 Sep; 1111:245-58.
- Shubitz LF, Dial SM, Galgiani JN. T-lymphocyte predominance in lesions of canine *Coccidioidomycosis*. *Vet Pathol* 2011 Sep; 48(5):1008-11.
- Cox RA, Magee DM. Protective immunity in *Coccidioidomycosis*. *73rd Forum In Immunology* 1998;417-28.
- Butkiewicz CD, Shubitz LE, Dial SM. Risk factors associated with *Coccidioides* infection in dogs. *J Am Vet Med Assoc* 2005 Jun 1; 226(11):1851-4.
- Greene RT, Troy GC. *Coccidioidomycosis* in 48 cats: a retrospective study (1984-1993). *J Vet Intern Med* 1995 Mar; 9(2):86-91.
- Johnson LR, Herrgesell EJ, Davidson AP, Pappagianis D. Clinical, clinicopathologic, and radiographic findings in dogs with *Coccidioidomycosis*: 24 cases (1995-2000). *J Am Vet Med Assoc* 2003



CLINICAL REVIEW

- Feb 15; 222(4):461-6.
31. Crabtree AC, Keith DG, Diamond HL. Relationship between radiographic hilar lymphadenopathy and serologic titers for *Coccidioides* sp. in dogs in an endemic region. *Vet Radiol Ultrasound* 2008 Nov; 49(6):501-3.
 32. Shubitz LF. Comparative aspects of Coccidioidomycosis in animals and humans. *Ann N Y Acad Sci* 2007 Sep; 1111:395-403.
 33. Ramirez-Romero R, Silva-Perez RA, Lara-Arias J, et al. Coccidioidomycosis in biopsies with presumptive diagnosis of malignancy in dogs: Report of three cases and comparative discussion of published reports. *Mycopathologia* 2016; 181:151-7.
 34. Shubitz LF, Dial SM. Coccidioidomycosis: a diagnostic challenge. *Clin Tech Small Anim Pract* 2005 Nov; 20(4):220-6.
 35. Higgins JC, Pusterla N, Pappagianis D. Comparison of *Coccidioides immitis* serological antibody titres between forms of clinical Coccidioidomycosis in horses. *Vet J* 2005 Oct 21; 173(1):118-123.
 36. Durkin M, Connolly P, Kuberski T, et al. Diagnosis of Coccidioidomycosis with use of the *Coccidioides* antigen enzyme immunoassay. *Clin Infect Dis* 2008 Oct 15; 47(8):e69-e73.
 37. Durkin M, Estok L, Hospenhal D, et al. Detection of *Coccidioides* antigenemia following dissociation of immune complexes. *Clin Vaccine Immunol* 2009 Oct; 16(10):1453-6.
 38. Foy DS, Trepanier LA, Kirsch EJ, Wheat LJ. Serum and urine blastomyces antigen concentrations as markers of clinical remission in dogs treated for systemic blastomycosis. *J Vet Intern Med* 2014 Mar; 28(2):305-10.
 39. Renschler JS, Holbrook ED, Wheat LJ. Improved sensitivity for detection of coccidioidomycosis in dogs with combined antibody and antigen testing. Poster session presented at: 61st Annual Coccidioidomycosis Study Group Meeting; 2017 Aug 10-13, Stanford, CA.
 40. Coster ME, Ramos-Vara JA, Vemulapalli R, Stiles J, Krohne SG. *Coccidioides posadasii* keratouveitis in a llama (*Lama glama*). *Vet Ophthalmol* 2010 Jan; 13(1):53-7.
 41. Plumb D. *The Veterinary Drug Handbook*. 4th ed. 2002.
 42. Plotnick AN, Boshoven EW, Rosychuk RAW. Primary cutaneous Coccidioidomycosis and subsequent drug eruption to itraconazole in a dog. *J Am Anim Hosp Assoc* 1997; 33(2):139-43.
 43. Renschler JS, Albers AJ, Sinclair-Mackling HR and Wheat LJ. Comparison of compounded, generic and innovatorformulated itraconazole in dogs and cats. *J Am Anim Hosp Assoc* (in press).
 44. Kim MM, Vikram HR, Kusne S, Seville MT, Blair JE. Treatment of refractory Coccidioidomycosis with voriconazole or posaconazole. *Clin Infect Dis* 2011 Dec; 53(11):1060-6.
 45. Herrin KV, Miranda A, Loebenberg D. Posaconazole therapy for systemic Coccidioidomycosis in a chimpanzee (*Pan troglodytes*): a case report. *Mycoses* 2005 Nov; 48(6):447-52.
 46. Gonzalez GM. In vitro activities of isavuconazole against opportunistic filamentous and dimorphic fungi. *Med Mycol* 2009 Feb; 47(1):71-6.
 47. Shubitz LF, Roy ME, Nix DE, Galgiani JN. Efficacy of Nikkomycin Z for respiratory Coccidioidomycosis in naturally infected dogs. *Med Mycol* 2013 Oct; 51(7):747-54.
 48. Cordeiro RA, Brilhante RS, Rocha MF, et al. In vitro activities of caspofungin, amphotericin B and azoles against *Coccidioides posadasii* strains from Northeast, Brazil. *Mycology* 2006 Jan; 161(1):21-6.
 49. Gonzalez GM, Gonzalez G, Najvar LK, Graybill JR. Therapeutic efficacy of caspofungin alone and in combination with amphotericin B deoxycholate for Coccidioidomycosis in a mouse model. *J Antimicrob Chemother* 2007 Oct 12.
 50. Antony S. Use of the echinocandins (caspofungin) in the treatment of disseminated Coccidioidomycosis in a renal transplant recipient. *Clin Infect Dis* 2004; 39:879-80.
 51. Park DW, Sohn JW, Cheong HJ, et al. Combination therapy of disseminated Coccidioidomycosis with caspofungin and fluconazole. *BMC Infect Dis* 2006; 6:26.

HEADQUARTERS

4705 Decatur Blvd. | Indianapolis, Indiana 46241, USA

888-841-8387